# 134 Ultraviolet Therapy

*Herbert Hönigsmann† and Thomas Schwarz*

## Chapter Contents

Phototherapy with UVB . . . . . 2362
Phototherapy with the 308 nm Excimer Laser or Lamp. . . . . 2367
Phototherapy with UVA1. . . . . 2367
Photochemotherapy with Psoralens (PUVA) . . . . . 2367
Extracorporeal Photochemotherapy (Photopheresis). . . . . 2376

## Key features

- Phototherapy represents the use of ultraviolet (UV) radiation for the treatment of skin diseases
- Currently, phototherapy encompasses irradiation with broadband UVB (290–320 nm), narrowband UVB (311–313 nm), 308 nm excimer laser, UVA1 (340–400 nm), UVA (320–400 nm) plus psoralens (PUVA) or alone, and extracorporeal photochemotherapy (photopheresis)
- Therapeutic success depends upon proper selection of the phototherapy modality for a given disease
- Proper dosimetry is required to avoid acute side effects such as a sunburn reaction, blistering, and burning sensations
- The risk of skin carcinogenesis represents the major long-term side effect of phototherapy; with the exception of PUVA, the magnitude of this risk is not yet clearly delineated

## INTRODUCTION

Over the past half-century, phototherapy has greatly influenced treatment concepts in dermatology. Studies focusing on the effects of electromagnetic radiation (Fig. 134.1) on the skin have induced fruitful collaborations between basic scientists and clinicians.

Although ultraviolet (UV) radiation had been used for decades in the management of common skin diseases such as psoriasis and atopic dermatitis, the introduction of PUVA in the mid-1970s sparked a whole new series of discoveries, including high-intensity UV sources and selective spectra in the UVB and UVA range, e.g. narrowband UVB (311–313 nm) and UVA1 (340–400 nm).

## PHOTOTHERAPY WITH UVB

### Historical Aspects

To date, the only dermatologist to be awarded a Nobel Prize in medicine was Dr Niels Finsen in 1903. The award recognized his demonstration of the beneficial effect of UV radiation on lupus vulgaris, and he eventually became known as the "father of photomedicine". The combination of topical crude coal tar followed by UV irradiation for the treatment of psoriasis was introduced by Goeckerman in 1925 and became a standard therapy for psoriasis for half a century, particularly in the US. In the 1970s, it was observed that broadband (BB) UVB radiation alone, if given in doses that produce a slight erythema, could clear the milder forms of psoriasis, particularly the guttate type. In the 1980s, the discovery that the combination of psoralens with UVA (PUVA) exerts potent anti-inflammatory effects opened a new era of phototherapy. A further major advance was the development of fluorescent bulbs that emitted narrowband (NB) UVB radiation at 311–313 nm in the mid-1980s. This narrow spectrum is superior in clearing psoriasis and thus represents the most effective and most frequently used UVB phototherapy for psoriasis; it is also beneficial for a variety of other dermatoses that were previously treated with PUVA (see below).

### Principles and Mechanisms

UVB phototherapy refers to the use of artificial UVB radiation without the addition of exogenous photosensitizers. The radiation is absorbed by endogenous chromophores, and photochemical reactions involving these UV-absorbing biomolecules mediate a variety of biologic effects, ultimately leading to the therapeutic effects. The most important chromophore for UVB is nuclear DNA. Absorption of UV by nucleotides causes the formation of DNA photoproducts, primarily pyrimidine dimers (see Ch. 86)[1].

UVB exposure reduces DNA synthesis and thus is used to suppress the accelerated DNA synthesis found in psoriatic epidermal cells. UVB also induces the expression of the tumor suppressor gene *TP53*, and this can lead to either cell cycle arrest (allowing time for DNA repair) or apoptosis of keratinocytes ("sunburn cells") if the DNA damage is too severe to be repaired. Through these mechanisms, p53 prevents photocarcinogenesis.

In addition to its effect on the cell cycle, UV induces the release of prostaglandins and cytokines. Interleukin (IL)-6 and IL-1, for example, seem to play important roles in producing the systemic symptoms of UV phototoxicity (sunburn) and immune suppression, respectively[1]. There is also increasing evidence that UV radiation can affect, in addition to DNA, extranuclear molecular targets located in the cytoplasm and cell membrane. These targets include cell surface receptors, kinases, phosphatases, and transcription factors. It was shown that nuclear and cytoplasmic/membrane effects are not mutually exclusive – rather they independently contribute to the multiple biologic effects of UVB.

Many of the therapeutic effects of UVB may be due to its immunosuppressive properties which have been linked to the formation of pyrimidine dimers. UV radiation suppresses contact allergy, delayed-type hypersensitivity, and immune surveillance against UV-induced keratinocyte carcinomas in mice. Of note, Langerhans cells are very sensitive to UVB, which alters their antigen-presenting function. Keratinocytes also secrete soluble mediators such as IL-1 and IL-6, prostaglandin $E_2$, and TNF in response to UVB, which by themselves can alter the immune response. Therapeutic UVB suppresses the type 1 (proinflammatory) axis as defined by IL-12, interferon (IFN)-γ, and IL-8, and can selectively reduce proinflammatory cytokine production by individual T cells[1].

The interplay of the various photobiological pathways is far from being completely understood. In psoriasis, both epidermal keratinocytes and cutaneous lymphocytes may be targeted by UVB. Immune suppression, alteration of cytokine expression, and cell cycle arrest may all contribute to the suppression of disease activity in psoriatic plaques[2]. In addition, a subset of T cells, Th17 cells, which seem to play a central role in the immunopathogenesis of psoriasis, are also downregulated by UVB[3]. More recently, evidence was presented that keratinocyte apoptosis may be a key mechanism in the clearance of psoriatic plaques[4].

### Action Spectrum and Radiation Sources

Parrish and Jaenicke[5] demonstrated that for antipsoriatic activity, 304 and 313 nm were the optimally effective wavelengths (Fig. 134.2), even at suberythemogenic doses. Erythemogenic UVA doses are also therapeutically effective, but 1000 times higher fluences are needed



Downloaded for Anonymous User (n/a) at Egyptian Knowledge Bank from ClinicalKey.com by Elsevier on March 10, 2024. For personal use only. No other uses without permission. Copyright ©2024. Elsevier Inc. All rights reserved.

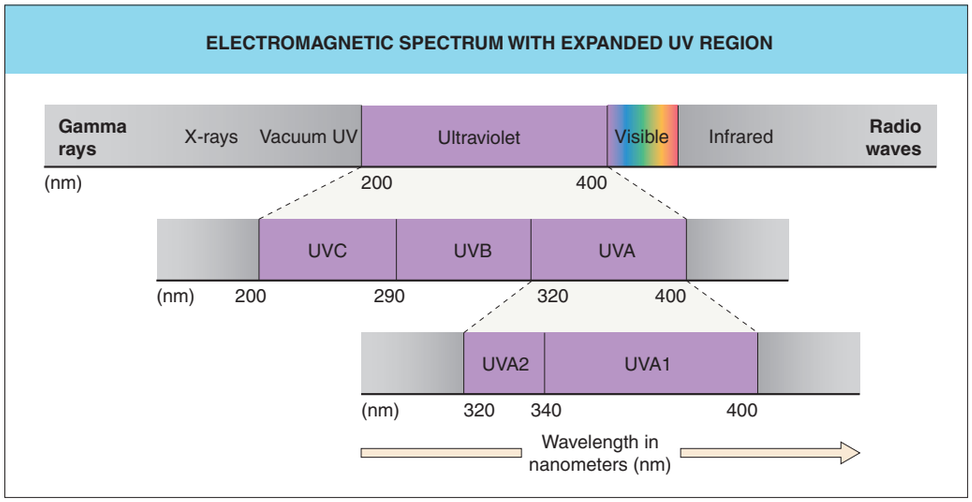


**Fig. 134.1 Electromagnetic spectrum with expanded UV region.**

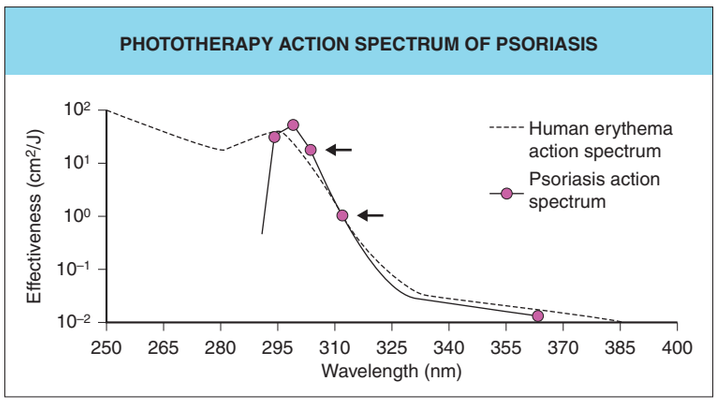


**Fig. 134.2 Phototherapy action spectrum of psoriasis.** The phototherapy action spectrum of psoriasis is plotted as the reciprocal of the lowest effective daily dose to clearing versus wavelength. Circles represent the reciprocal of the lowest effective daily dose for wavelengths that cleared psoriasis (295, 300, 304, 313, 365 nm); the arrows point to the wavelengths that were optimally effective (304, 313 nm). Presently, narrowband UVB sources that emit wavelengths between 311 and 313 nm are available. *Adapted from Parrish JA, Jaenicke KF. Action spectrum for phototherapy of psoriasis. J Invest Dermatol 1981;76:359–62.*

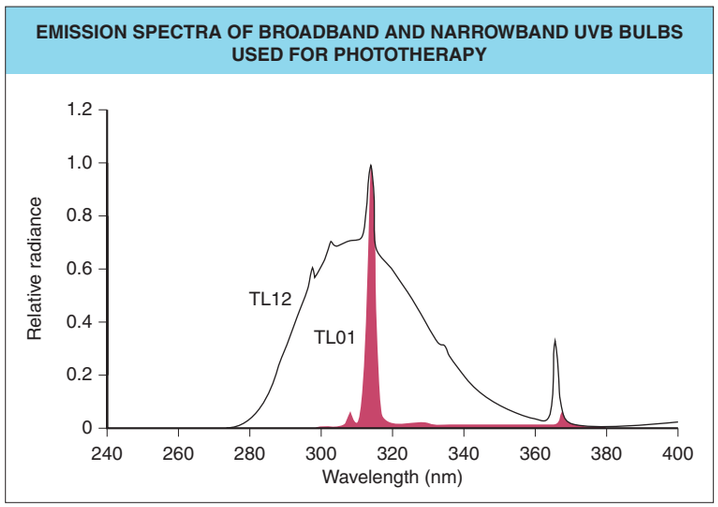


**Fig. 134.3 Emission spectra of broadband and narrowband UVB bulbs used for phototherapy.** Philips TL12, broadband UVB bulb; Philips TL01, narrowband UVB bulb.

(as compared with UVB) which practically speaking is not feasible. The addition of UVA also does not enhance the therapeutic efficacy of UVB in psoriasis (unlike atopic dermatitis). The Philips TL01 fluorescent lamp that emits NB-UVB (311–313 nm) was introduced to optimally meet the requirements for antipsoriatic activity (Fig. 134.3).

Devices that contain UV radiation-emitting bulbs are available in a wide range of sizes and designs including enclosed whole-body cabinets, portable flat panels, and hand-held units. When reliable patients live far distances from physician-supervised phototherapy centers or for other reasons are unable to schedule multiple treatments per week, UVB units designed for home use can be utilized. Practical guidelines for home phototherapy have been published[6].

Exposure to natural sunlight is called heliotherapy. Natural sunlight contains sufficient UVB radiation such that it is sometimes used to treat photoresponsive dermatoses. However, due to variables that affect UVB irradiance, including time of day, cloud cover, season, altitude and latitude, appropriate exposure times cannot be standardized. As a result, there is a greater probability of sunburn and an inadequate therapeutic response.

## Treatment Protocols

Over the past several years, a number of dermatologic societies have published guidelines for utilizing phototherapy. They all provide more or less similar recommendations with some slight variations which are due to national differences in the health care system, reimbursement, legal requirements, availability/approval of alternative therapies, and of course traditions regarding prescribing practices. Table 134.1 lists some of the available guidelines. Most of these guidelines are updated regularly and are made available through online sources.

Before starting phototherapy, determination of the patient's UV sensitivity via phototesting is frequently recommended, since skin typing by history alone does not always reflect the actual sensitivity of a particular individual. However, phototesting is not mandatory for the experienced therapist and, for practical reasons, is often not done. Testing is performed by exposing four to six small template areas (e.g. 1 cm diameter circles or squares) of usually non-sun-exposed skin (lower back, buttocks) to an incremental series of UVB doses. In successive test sites, the incremental increases can be fixed (e.g. 10 or 20 mJ/cm$^2$) or proportional (e.g. 40% higher). An example is given in Table 134.2. Note that the actual doses delivered as specified in fluence units (mJ/cm$^2$) strongly depend on the type of UVB unit; for example, NB-UVB is much less erythemogenic than BB-UVB and consequently higher numerical doses are required.

The minimal erythema dose (MED) is defined as the lowest dose that causes a minimally perceptible erythema reaction at 24 hours after irradiation. Sunbathing or exposure to tanning lamps should be avoided before phototesting. It is crucial to document the type of lamp used for the MED determination, since the values obtained with broadband and narrowband sources differ by up to ten-fold (see Table 134.2).

Despite continued discussion as to whether visual assessment of the MED is the optimal method for establishing the initial UVB dose, it



Downloaded for Anonymous User (n/a) at Egyptian Knowledge Bank from ClinicalKey.com by Elsevier on March 10, 2024. For personal use only. No other uses without permission. Copyright ©2024. Elsevier Inc. All rights reserved.

| EXAMPLES OF NATIONAL PHOTOTHERAPY GUIDELINES |
|---|
| **Dosimetry** |
| Moseley H, Allan D, Amatiello H, et al. Guidelines on the measurement of ultraviolet radiation in ultraviolet phototherapy: report issued by the British Association of Dermatologists and British Photodermatology Group 2015. Br J Dermatol 2015;173:333–50. |
| **Ultraviolet B** |
| Ibbotson SH, Bilsland D, Cox NH, et al. An update and guidance on narrowband ultraviolet B phototherapy: a British Photodermatology Group Workshop Report. Br J Dermatol 2004;151:283–97. |
| Mehta D, Lim HW. Ultraviolet B phototherapy for psoriasis: review of practical guidelines. Am J Clin Dermatol 2016;17:125–33. |
| Elmets CA, Lim HW, Stoff B, et al. Joint American Academy of Dermatology-National Psoriasis Foundation guidelines of care for the management and treatment of psoriasis with phototherapy. J Am Acad Dermatol 2019;81:775–804.* |
| Mohammad TF, Al-Jamal M, Hamzavi IH, et al. The Vitiligo Working Group recommendations for narrowband ultraviolet B light phototherapy treatment of vitiligo. J Am Acad Dermatol 2017;76:879–88. |
| **Psoralens plus UVA (PUVA) and/or UVA1** |
| Ling TC, Clayton TH, Crawley J, et al. British Association of Dermatologists and British Photodermatology Group guidelines for the safe and effective use of psoralen-ultraviolet A therapy 2015. Br J Dermatol 2016;174:24–55. |
| Herzinger T, Berneburg M, Ghoreschi K, et al. S1-Guidelines on UV phototherapy and photochemotherapy. J Dtsch Dermatol Ges 2016;14:853-76.† |
| Halpern SM, Anstey AV, Dawe RS, et al. Guidelines for topical PUVA: a report of a workshop of the British photodermatology group. Br J Dermatol 2000;142:22–31. |
| **Cutaneous T cell lymphoma (CTCL)** |
| Olsen EA, Hodak E, Anderson T, et al. Guidelines for phototherapy of mycosis fungoides and Sézary syndrome: a consensus statement of the United States Cutaneous Lymphoma Consortium. J Am Acad Dermatol 2016;74:27–58. |
| **Photopheresis** |
| Knobler R, Arenberger P, Arun A, et al. European dermatology forum – updated guidelines on the use of extracorporeal photophoresis 2020 – part 1. J Eur Acad Dermatol Venereol 2020;34:2693–716. |
| Knobler R, Arenberger P, Arun A, et al. European dermatology forum – updated guidelines on the use of extracorporeal photophoresis 2020 – part 2. J Eur Acad Dermatol Venereol 2020;35:27–49. |
| *Also reviews PUVA and excimer laser. |
| †Also reviews UVB. |

**Table 134.1 Examples of national phototherapy guidelines.**

| RECOMMENDED EXPOSURE DOSES (FLUENCES) FOR MED PHOTOTESTING TO BROADBAND AND NARROWBAND UVB SOURCES (mJ/cm$^2$) | | | | | | |
|---|---|---|---|---|---|---|
| Broadband UVB | 20 | 40 | 60 | 80 | 100 | 120 |
| Narrowband UVB | 200 | 400 | 600 | 800 | 1000 | 1200 |

$$\text{Time (sec)} = \frac{\text{Fluence (delivered dose of UV in mJ/cm}^2\text{ [UVB] or J/cm}^2\text{ [UVA])}}{\text{Irradiance (measured UV intensity expressed in mW/cm}^2\text{ [UVB] or W/cm}^2\text{ [UVA])}}$$

**Table 134.2 Recommended exposure doses (fluences) for minimal erythema dose (MED) phototesting to broadband and narrowband UVB sources (mJ/cm$^2$).** 1 watt (W) = 1 joule (J) of energy per second.

is an easily performed procedure that does not require any specialized equipment. An initial therapeutic UVB dose equal to 70% of the MED is typically recommended. Subsequent treatments are given two to five times weekly. Since UVB erythema peaks within 24 hours after exposure, doses may be increased with each successive treatment. However, if treatments are given five times weekly, the doses should be increased every other treatment. The rate of increase depends on treatment frequency and the response to the preceding UVB exposure. The objective of the dose increments is to achieve a minimally perceptible erythema as a clinical indicator of optimal dosimetry. For example, with thrice-weekly exposures, doses are increased by a maximum of 40% if no erythema appears, and by a maximum of 20% upon development of slight erythema. If mild erythema persists, the dose should be maintained. With daily exposures, these rates are no more than 30%, 15% and 0%, respectively. If more intensive or painful erythema develops, irradiations are stopped until the symptoms disappear. Treatment is then continued until complete remission is achieved or no further improvement can be obtained with continued phototherapy (Fig. 134.4).

Whether maintenance treatment leads to a more prolonged remission time is still a matter of debate, since minimal precise data are available. In cutaneous T cell lymphoma (CTCL), most therapists perform maintenance treatment for several months to a year. For psoriasis, some centers use a 2-month maintenance phase with twice-weekly exposures for 1 month and once-weekly exposures for another month. The last effective UVB dose is given throughout the maintenance phase. If relapses occur during the maintenance phase, treatment frequency and UVB dose are again increased until clearing. Of note, there was some evidence in a randomized study that maintenance NB-UVB may lead to longer remission times in plaque-type psoriasis[7].

## Phototherapy for Psoriasis

Guttate psoriasis and minimally elevated lesions of psoriasis respond most favorably and rapidly to BB-UVB, while chronic, plaque-type psoriasis is more resistant. In terms of clearing efficiency and duration of remission, BB-UVB is inferior to both NB-UVB and PUVA. As a result, in many countries, NB-UVB has largely replaced conventional BB-UVB phototherapy. Based on several publications, NB-UVB phototherapy appears to be somewhat less effective than PUVA.

In addition to the treatment protocols mentioned above, other regimens may be used. Some schedules utilize skin type-dependent starting doses and fixed increments regardless of skin reaction. Sometimes, the patient's extremities (in particular the lower extremities which tend to respond more slowly) can be exposed to higher doses than the trunk.

Adjunctive topical agents and combination therapies are often used to improve efficacy and reduce the cumulative UVB dose, with the ultimate aim of minimizing the risk of long-term side effects. Narrowband UVB has been successfully combined with therapies such as anthralin and vitamin D analogues. The use of bland emollients before UVB treatment is laborious and time-consuming, and in our experience does not dramatically increase treatment efficacy. The concurrent use of topical corticosteroids may reduce remission times and thus is discouraged by some dermatologists.

Systemic drugs such as retinoids increase efficacy, particularly in patients with chronic plaque-type psoriasis[8,9]. In addition, retinoids may reduce the carcinogenic potential of UVB phototherapy. There have been open-label studies and small comparison studies regarding the efficacy of combining UVB phototherapy with systemic immunomodulators ("biologics")[10,11]. To date, there have been no large-scale studies, and long-term data, including remission times, are unavailable.

## Phototherapy for Cutaneous T Cell Lymphoma, in Particular Mycosis Fungoides

For early stages (IA, IB, and IIA) of mycosis fungoides (MF), conventional treatment strategies include topical corticosteroids, UV radiation, topical retinoids (e.g. bexarotene), and topical cytotoxic agents (e.g. mechlorethamine [nitrogen mustard]). More advanced stages are treated with various combinations that include total body electron beam radiation therapy (see Ch. 139), local radiotherapy, systemic retinoids, PUVA, systemic chemotherapy (e.g. gemcitabine), and immunomodulators (e.g. brentuximab vedotin, mogamulizumab, IFN) (see Table 120.5), but none of these regimens have been demonstrated to induce permanent remission.

Lesions of MF frequently occur in non-sun-exposed areas of the body, and patients with early stage MF often benefit from exposure to natural sunlight. Response to phototherapy is related to the type (i.e. patch stage MF does better than the plaque type) but not the extent of skin involvement. In a more recent study, prolonged maintenance therapy (up to 30 months) resulted in a relapse-free period of 26 ± 10 months[12].



Downloaded for Anonymous User (n/a) at Egyptian Knowledge Bank from ClinicalKey.com by Elsevier on March 10, 2024. For personal use only. No other uses without permission. Copyright ©2024. Elsevier Inc. All rights reserved.

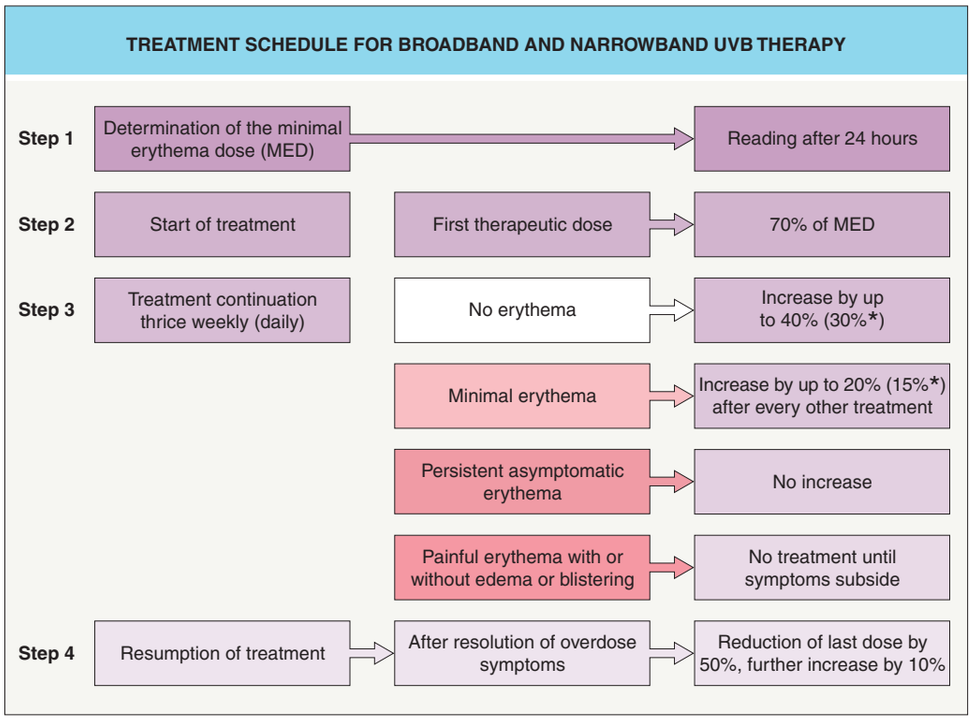


**Fig. 134.4 Treatment schedule for broadband and narrowband UVB therapy.** *If treatments are given five times per week or daily.

The proposed mechanisms for UVB phototherapy of MF include impairment of epidermal Langerhans cell function and alterations in cytokine production and adhesion molecule expression by keratinocytes[13]. Moreover, NB-UVB can induce apoptosis of T lymphocytes, which may more specifically contribute to the beneficial effect of this light source[14].

UVB phototherapy is clearly less efficient than PUVA, and the duration of treatment in the clearing and maintenance phases is longer and thus requires higher patient compliance. Whether patients would benefit from adding UVA, as is sometimes recommended, remains questionable. Likewise, NB-UVB and BB-UVB therapy have not been compared in MF. It is possible that combining a systemic retinoid (e.g. bexarotene) with NB-UVB may increase efficacy. Lastly, a pilot study documented the efficacy of medium- to high-dose UVA1 therapy (see below) in patients with stage IA and IB MF. However, there is no evidence that UVA1 is superior to PUVA and no long-term follow-up is available.

## Phototherapy for Vitiligo

Many patients observe follicular repigmentation in areas of vitiligo following sun exposure. Because of seasonal and weather-dependent variations in sunlight intensity in moderate climates, exposure to natural sunlight is often not a practical option for inducing repigmentation. In the past, PUVA was most frequently used for the treatment of vitiligo, but exposure to artificial UVB irradiation, in particular NB-UVB, can also provide an acceptable therapeutic effect, if given for a sufficiently long period. Although the action spectrum for phototherapy of vitiligo is not known, NB-UVB has clearly become quite popular in recent years. In comparison studies of NB-UVB with PUVA, NB-UVB was as effective as PUVA but had fewer side effects (Fig. 134.5). Also, in a randomized double-blind trial of non-segmental vitiligo, NB-UVB therapy was superior to oral PUVA therapy and the color match of repigmented skin was considered to be better in the patients treated with NB-UVB[15]. UVA alone is of limited benefit.

Since intense erythema may induce the Koebner phenomenon and worsening of the disease, it is necessary to stay within a dose range that induces minimally perceptible erythema. Therefore, initial assessment of the MED in a vitiliginous area that is normally not sun-exposed (e.g. buttocks, lower back, abdomen) is recommended. The UVB doses have to be increased more carefully than in other disorders, because of the increased photosensitivity of depigmented skin.

The initial exposure is 70% of the MED in lesional skin, and subsequent doses are chosen according to the response in vitiligo areas, i.e. the goal is to induce a barely perceptible erythema that has a light pink color. The presence or absence of faint erythema is the only useful parameter for determining dosage increments. The dose should not be increased more than once weekly by 5%–20% of the preceding dose. Despite the lack of pigment, vitiliginous skin does develop photoadaptation, probably as a

**Fig. 134.5 Narrowband UVB phototherapy for vitiligo. A** Before treatment. **B** After 10 months of treatment (twice weekly). Note the persistence of depigmentation of the areolae, an area which is particularly resistant to treatment.



Downloaded for Anonymous User (n/a) at Egyptian Knowledge Bank from ClinicalKey.com by Elsevier on March 10, 2024. For personal use only. No other uses without permission. Copyright ©2024. Elsevier Inc. All rights reserved.

result of epidermal hyperplasia and thickening of the stratum corneum. In contrast to previous assumptions, the risk of developing keratinocyte carcinoma is not enhanced in vitiliginous areas. Usually, a maximum dose will be reached during the first couple of months which is then used throughout the entire treatment period. Most commonly, two to three treatments per week are given. Although few controlled studies are available for any particular phototherapy regimen to be preferred over another, consensus recommendations are available[16].

More recently, the combination of an afamelanotide implant plus NB-UVB phototherapy resulted in clinically apparent, statistically significant superior and faster repigmentation compared with NB-UVB monotherapy. Afamelanotide is an analogue of α-melanocyte stimulating hormone that can induce diffuse hyperpigmentation of the skin, especially in sun-exposed sites. Of note, the response was more noticeable in patients with skin phototypes IV to VI[17]. Enhanced repigmentation with a combination of NB-UVB plus topical 1.5% ruxolitinib cream twice daily has also been reported[17a].

## Phototherapy for Atopic Dermatitis

### *Broadband UVB (BB-UVB) phototherapy*

Based on the empirical experience that sun exposure is beneficial for patients with atopic dermatitis, BB-UVB has been used to treat atopic dermatitis since the late 1970s.

### *UVA/UVB phototherapy*

Subsequent studies suggested that a combination of UVA plus UVB irradiation (UVA/UVB therapy) is superior to conventional BB-UVB, conventional UVA, or low-dose UVA1 therapy in the management of chronic, moderate atopic dermatitis. A paired-comparison study demonstrated statistically significant differences in favor of UVA/UVB therapy, compared with BB-UVB therapy[18].

### *Narrowband UVB (NB-UVB) phototherapy*

Earlier studies showed that NB-UVB irradiation not only improved the total clinical score, but also substantially reduced the need for topical corticosteroids. These beneficial effects were still present in the majority of patients 6 months after cessation of phototherapy. Narrowband UVB therapy has also been used successfully in conjunction with UVA1 therapy. However, due to the lack of baseline data on the duration and severity of atopic dermatitis, a final conclusion on preference of phototherapy in the acute or chronic phases cannot be drawn from available studies[19].

## Phototherapy for Photodermatoses

In the majority of patients, polymorphous light eruption (PMLE) gradually abates with continual outdoor light exposure. For patients prone to PMLE, NB-UVB phototherapy can be used prophylactically to induce "hardening" of the skin before a vacation to a sunny climate or during the springtime (see Ch. 87). Two to three treatments per week for a total of 12–15 sessions are typically administered prior to an anticipated increase in exposure to sunlight. Despite using reduced UVB doses (as compared to those for psoriasis), this phototherapy regimen can induce a transient photoeruption; the latter usually responds to topical corticosteroids and smaller incremental increases in subsequent UVB doses. The precise mechanisms by which phototherapy induces adaptation to sunlight are not known, but may include thickening of the stratum corneum and modulation of cutaneous immune functions. This phenomenon is not due to hyperpigmentation, as was previously thought – patients with skin phototype I respond equally well to NB-UVB as other skin phototypes.

Narrowband UVB phototherapy has also been shown to be capable of inducing "hardening" in patients with erythropoietic protoporphyria, actinic prurigo, and solar urticaria[20]. For solar urticaria, however, the UVA rush hardening regimen appears to be preferable, since effective protection can be achieved within a few days with this protocol[21].

## Phototherapy for Pityriasis Lichenoides

Both pityriasis lichenoides acuta and chronica can have a prolonged course and be rather resistant to therapy. As sunlight may lead to some improvement, UVB phototherapy has also been associated with some success. However, PUVA seems to be more effective (see below), especially in the acute form of the disease (perhaps because of the deeper extension of the dermal inflammatory infiltrate). Although some authors have recommended PUVA as the treatment of choice for the acute form[22], PUVA may be reserved for cases of pityriasis lichenoides chronica that are UVB-resistant.

## Phototherapy for Seborrheic Dermatitis

Facial and truncal seborrheic dermatitis generally improves during the summer and "sunny" vacations. Accordingly, UV radiation also seems to have a beneficial effect on this condition. However, flares of dermatitis may occasionally occur. In an open prospective study, NB-UVB was found to be an effective treatment in severe cases[23]. Nonetheless, because topical therapies lead to improvement of seborrheic dermatitis in the majority of patients, phototherapy does not represent a first-line treatment.

## Phototherapy for Pruritus

Both NB- and BB-UVB therapy can be of benefit in various forms of pruritus, particularly those associated with diabetes and renal or hepatic disorders, as well as in idiopathic pruritus. However, in patients with cholestatic pruritus, remissions are relatively short-lived. In a case series, NB-UVB led to improvement of uremic pruritus[24].

## Side Effects of Phototherapy With UVB

Short-term side effects include erythema (Fig. 134.6), xerosis accompanied by pruritus, occasional blistering, and an increased frequency of recurrent herpes simplex viral infections. Painful erythema resulting from overexposure is treated with topical corticosteroids. Systemic nonsteroidal anti-inflammatory drugs and corticosteroids can prove useful in severe cases if administered early.

Long-term side effects include photoaging and carcinogenesis. Although UVB is a known carcinogen, its carcinogenic potential seems to be much lower than that of PUVA. In a British study involving 3867 patients who had been treated with NB-UVB, no significant association between NB-UVB treatment and basal cell carcinoma (BCC), squamous cell carcinoma (SCC), or melanoma was found[25]. There was a small increase in BCCs amongst those patients who had also been previously treated with PUVA. To determine the true carcinogenic risk of NB-UVB phototherapy, additional longitudinal studies are essential.

**Fig. 134.6 Target-like appearance of psoriatic lesions secondary to phototoxicity due to UVB.** Annular erythema is separated from the psoriatic plaques by Woronoff's ring.



Downloaded for Anonymous User (n/a) at Egyptian Knowledge Bank from ClinicalKey.com by Elsevier on March 10, 2024. For personal use only. No other uses without permission. Copyright ©2024. Elsevier Inc. All rights reserved.

## PHOTOTHERAPY WITH THE 308 NM EXCIMER LASER OR LAMP

With the 308 nm excimer laser, monochromatic UVB radiation can be delivered to specific sites of affected skin at higher fluences than are typically administered with whole-body exposure. Clinical use of this laser for plaque-type psoriasis was first reported in 1997[26] and it is FDA-approved for this indication. Possible advantages are the lower number of treatments that may be necessary to induce clearing as well as the ability to selectively target affected skin with a reduced cumulative dose, thus perhaps reducing the long-term risk of carcinogenicity[27]. However, widespread psoriasis generally cannot be treated with this modality because the spot size is limited to just a few square centimeters.

Clearly, the excimer laser is most suitable for patients with stubborn plaques unresponsive to other treatments and/or those with difficult-to-treat localized areas such as the palms, soles, knees, and elbows. Whether it really represents a therapeutic advancement still remains to be determined by larger and longer-term studies, particularly in view of the high costs of laser treatments. However, both non-laser excimer lamps and hand-held targeted UV devices are less expensive and appear to be similarly effective[27].

Based upon case series, targeted phototherapy with the excimer laser or excimer lamp may also serve as a treatment modality for the management of stable vitiligo[28] as well as a variety of chronic inflammatory localized dermatoses such as granuloma annulare, lichen planus, lichen simplex chronicus, and alopecia areata[29].

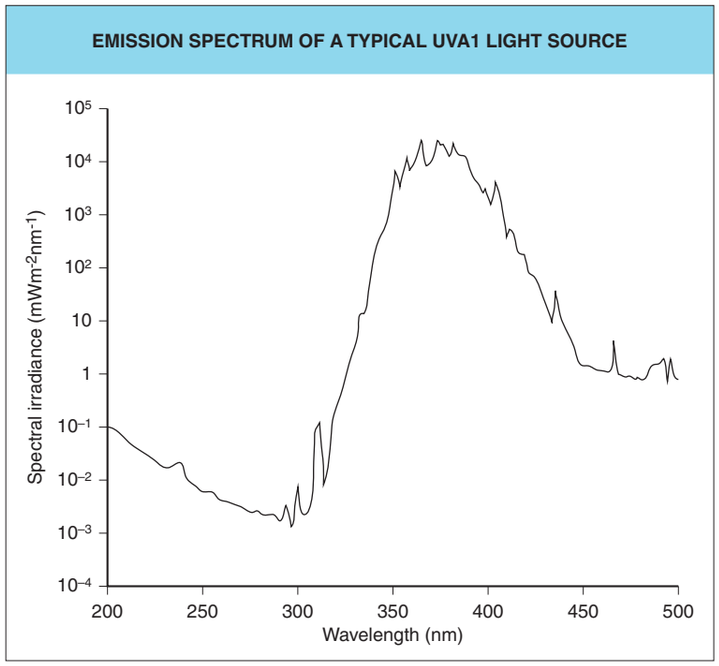


**Fig. 134.7 Emission spectrum of a typical UVA1 light source (filtered metal halide lamp).**

## PHOTOTHERAPY WITH UVA1

The UVA spectrum (320–400 nm) has been arbitrarily subdivided into two parts: UVA1 (340–400 nm) and UVA2 (320–340 nm) (see Fig. 134.1). The main reason for this subdivision was the observation that UVA2 resembled UVB in its ability to induce erythema, immunomodulation, and photocarcinogenesis. Because of its longer wavelength, UVA1 radiation penetrates more deeply into the skin than UVA2 (see Ch. 86), and thus it affects not only epidermal structures, but also mid and deep dermal components, especially blood vessels. Since the skin is a large organ, exposure of circulating immune cells to UVA1 irradiation may have significant systemic ramifications. In particular, its ability to induce T lymphocyte apoptosis is likely to be relevant in the treatment of atopic dermatitis. UVA1 irradiation may also reduce the number of Langerhans cells and mast cells in the dermis in atopic dermatitis and cutaneous mastocytosis. In addition, it has been shown that increased collagenase expression in treated lesions of localized scleroderma (morphea) accompanies improvement with UVA1 irradiation. Perhaps the efficacy of UVA1 in localized scleroderma, and in other sclerosing conditions, is in part due to this action.

UVA1 phototherapy has been investigated as a safer alternative to PUVA for treating chronic conditions. Its major disadvantages are the higher fluences (e.g. 30–130 J/cm$^2$ per session) and therefore exposure times that are required as well as the higher costs for the lamps. To date, most of the UVA1 studies have been performed in Europe, where efficient sources of UVA1 radiation are more widely available (Fig. 134.7).

UVA1 can have a therapeutic effect on atopic dermatitis[30,31] (Fig. 134.8). It seems to be more effective than UVA/UVB therapy, at least for severe exacerbations of atopic dermatitis. If used as a monotherapy, medium and high daily doses are better than low doses. When UVA1 and NB-UVB were compared for the treatment of atopic dermatitis, they seemed to be equally effective[32]. However, as noted previously, there is currently no consensus as to the preferred type of UV phototherapy for atopic dermatitis[19].

UVA1 therapy has been reported to be beneficial in several other dermatoses[33], in particular sclerosing dermatoses[34], acute GVHD, and chronic sclerodermoid GVHD[35,36]. UVA1 has also been used to treat urticaria pigmentosa[33] and MF[37]. However, its efficacy, especially for the latter indication, requires confirmation in larger patient series.

### Side Effects of Phototherapy with UVA1

The adverse effects of UVA1 are less severe than those of UVB and UVA2, although the high fluences usually induce marked tanning, especially in more darkly pigmented individuals. Until more is known about UVA1 therapy, its use (especially with high doses such as 130 J/cm$^2$) should be limited to treating diseases with periods of severe, acute exacerbations, and in general, one treatment cycle should not exceed 15–20 successively administered exposures and should not be repeated more than once a year. A European prospective longitudinal study has been initiated to monitor patients treated with UVA1 phototherapy for the development of skin cancer and photoaging. An increased expression of *TP53* and a slight increase in Bcl-2 protein expression in keratinocytes were found in human skin after UVA1 irradiation (even with suberythemogenic doses), suggesting that UVA1 may cause DNA damage[38]. In addition, UVA1 induced pro-mutagenic cyclobutane pyrimidine dimers and oxidative DNA damage (at both the genomic and nucleotide resolution level) in normal human skin fibroblasts[39]. Of note, in the years since the widespread use of UVA1 phototherapy in Europe began in 1992, no serious negative side effects in humans have been reported.

## PHOTOCHEMOTHERAPY WITH PSORALENS (PUVA)

Psoralen photochemotherapy (PUVA) combines the use of psoralens (P) and long-wave UV radiation (UVA). This combination results in a therapeutically beneficial phototoxic effect, which is not produced by either of the components alone. Psoralens can be administered orally or applied topically in the form of solutions, creams, or baths with subsequent UVA exposure.

### Historical Aspects

Topical exposure to extracts, seeds, or parts of plants (e.g. *Ammi majus*, *Psoralea corylifolia*) that contain natural psoralens, followed by exposure to sunlight, was used as a remedy for vitiligo for thousands of years in ancient Egypt and India[40]. In 1974, it was shown that the oral ingestion of 8-methoxypsoralen (8-MOP) and subsequent exposure to a new, high-intensity, artificial UVA radiation source was highly effective for the treatment of psoriasis[41]. This was followed by recognition of its therapeutic effect for multiple skin disorders (Table 134.3). Over the past decade, the use of PUVA has decreased significantly, due in part to the increased risk of developing keratinocyte carcinomas and melanoma, especially with prolonged use in fair-skinned individuals, in addition to the effectiveness of NB-UVB and especially systemic



Downloaded for Anonymous User (n/a) at Egyptian Knowledge Bank from ClinicalKey.com by Elsevier on March 10, 2024. For personal use only. No other uses without permission. Copyright ©2024. Elsevier Inc. All rights reserved.

**Fig. 134.8 UVA1 phototherapy of atopic dermatitis (split-body comparison). A** Before treatment. **B** After treatment (15 exposures) with high-dose (130 J/cm$^2$, left side) *versus* medium-dose (65 J/cm$^2$, right side) UVA1 phototherapy. Note that there is no difference in the therapeutic result.

| PUVA-RESPONSIVE DISEASES | |
|---|---|
| **Therapy of disease** | **Prevention of disease** |
| Psoriasis | Polymorphic light eruption† |
| Palmoplantar pustulosis | Solar urticaria† |
| Atopic dermatitis | Chronic actinic dermatitis*,† |
| Mycosis fungoides (stages IA, IB, IIA) | Hydroa vacciniforme*,† |
| Vitiligo | |
| Generalized lichen planus | |
| Urticaria pigmentosa | |
| Cutaneous GVHD | |
| Generalized granuloma annulare | |
| Prurigo nodularis | |
| Pityriasis lichenoides (acute and chronic)* | |
| Lymphomatoid papulosis* | |
| Pityriasis rubra pilaris*,† | |
| Pigmented purpuric dermatoses* | |
| Langerhans cell histiocytosis* | |
| Localized scleroderma* | |

*Experience is limited to a small number of patients.
†These diseases may flare prior to therapeutic response.

**Table 134.3 PUVA-responsive diseases.** GVHD, graft-versus-host disease.

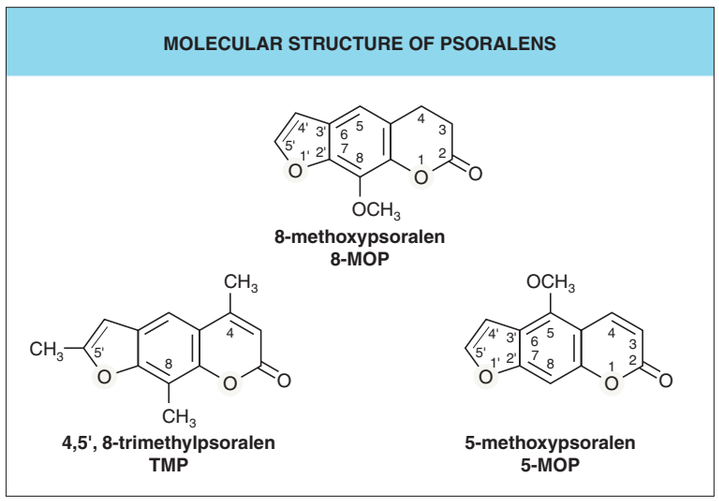


**Fig. 134.9 Molecular structure of psoralens.**

immunomodulators ("biologics") in psoriasis. Even though PUVA often represents a second-line form of phototherapy, it is essential that dermatologists become familiar with treatment regimens, potential side effects, and indications, in particular since it is still the (see meta-analysis below) therapy of choice in early stage mycosis fungoides.

## Psoralens

Psoralens are naturally occurring linear furocoumarins that are found in a large number of plants, and there are several synthetic psoralen compounds. For oral and topical (bath, cream) PUVA, mainly 8-MOP (methoxsalen) is used; it is of plant origin but also available as a synthetic drug. The synthetic compound, 4,5′,8-trimethylpsoralen (TMP, trioxsalen), is less phototoxic than 8-MOP after oral administration, but more phototoxic when delivered via bath-water. TMP had been used primarily in Scandinavia for bath PUVA. 5-Methoxypsoralen (5-MOP, bergapten) is also therapeutically effective when given orally; it is less erythemogenic and is not associated with gastrointestinal intolerance (Fig. 134.9). In some European countries, it was routinely used for PUVA, but it is no longer commercially available. Oral preparations of 8-MOP contain crystals, micronized crystals, or solubilized psoralens in a gel matrix. The latter liquid preparation induces earlier, higher, and more reproducible peak plasma levels than the crystalline preparations.

The steps between the ingestion of a psoralen and its arrival in the skin include disintegration and dissolution of the drug, absorption, first-pass effect, blood transport, and tissue distribution. The absorption rate of a psoralen from the gut depends on the physicochemical properties of the molecule, the rate of dissolution, the galenic characteristics of the preparation, and the fat content of concomitantly ingested food. Peak serum levels are usually reliably and predictably achieved by liquid preparations, whereas wide time variability occurs with crystalline formulations. Before reaching the skin via the circulation, psoralens are metabolized during their passage through the liver. Plasma levels of 8-MOP administered orally at different doses show a strong non-linearity, indicating a saturable first-pass effect. Thus, small differences in the ingested doses and absorption rates of psoralens lead to large differences in plasma levels. As a practical consequence, small amounts of the drug are almost completely metabolized by the liver during the first pass and therefore may be therapeutically inactive.



Downloaded for Anonymous User (n/a) at Egyptian Knowledge Bank from ClinicalKey.com by Elsevier on March 10, 2024. For personal use only. No other uses without permission. Copyright ©2024. Elsevier Inc. All rights reserved.

8-MOP serum levels show a wide range of inter-individual differences. Even on different occasions in the same patient, serum levels may differ; however, the levels are usually sufficiently constant to provide for relatively reproducible therapeutic results. This unpredictable pharmacokinetic behavior is probably due to inter- and intra-individual variations in intestinal absorption, first-pass effect, blood distribution in the body, and metabolism and elimination of the drug.

For a given patient, serum levels of 8-MOP correspond fairly well with skin reactivity, with the peak of skin phototoxicity coinciding with peak serum levels. A correlation between 8-MOP serum levels and epidermal concentrations does exist. Whether there is a significant correlation between maximum psoralen blood concentrations and the minimal phototoxicity dose (MPD) remains equivocal.

The pharmacokinetics of topical 8-MOP depend on the mode of application. 8-MOP administered topically as a 0.15% emulsion or solution has been shown to result in plasma levels comparable to those obtained by oral delivery, when large areas of the body are treated. In contrast, due to the much lower concentrations that are typically used, plasma levels following bath-PUVA treatment of almost the entire body surface are very low. Bath-water-delivered psoralens are readily absorbed into the skin, but promptly eliminated without cutaneous accumulation[2].

## *Psoralen photochemistry*

Psoralens react with DNA in three steps. First, in the absence of UV radiation, the psoralen intercalates into the DNA double strand. Via a photochemical reaction, absorption of photons in the UVA range results in the formation of a 3,4- or 4′,5′-cyclobutane monoadduct with pyrimidine bases of native DNA. The 4′,5′ monoadducts can absorb a second photon and this reaction leads to the formation of an interstrand cross-link of the double helix with the 5,6 double bond of the pyrimidine base of the opposite strand (Fig. 134.10).

UVA-activated psoralens can also react with molecular oxygen. The reactive oxygen species formed by this reaction cause cell membrane damage by lipid peroxidation and may activate the cyclooxygenase and arachidonic acid metabolic pathways.

The cross-linking of psoralens with epidermal DNA inhibits DNA replication and causes cell cycle arrest. Although not proven, it is generally assumed that this effect may be the therapeutic mechanism in psoriasis. Psoralen photosensitization also causes an alteration in the expression of cytokines and cytokine receptors. However, DNA cross-linking does not appear to be a prerequisite for all the therapeutic effects of PUVA, and the successful treatment of other skin diseases is unlikely to be due directly to this molecular reaction. Psoralens also interact with RNA, proteins, and other cellular components and indirectly modify proteins and lipids via singlet oxygen-mediated reactions or by generating free radicals[42,43].

PUVA can reverse the pathologically altered patterns of keratinocyte differentiation markers and reduce the number of proliferating epidermal cells. Infiltrating lymphocytes are strongly suppressed by PUVA, with variable effects on different T cell subsets. PUVA is far more potent in inducing apoptosis in lymphocytes than in keratinocytes[1], which may

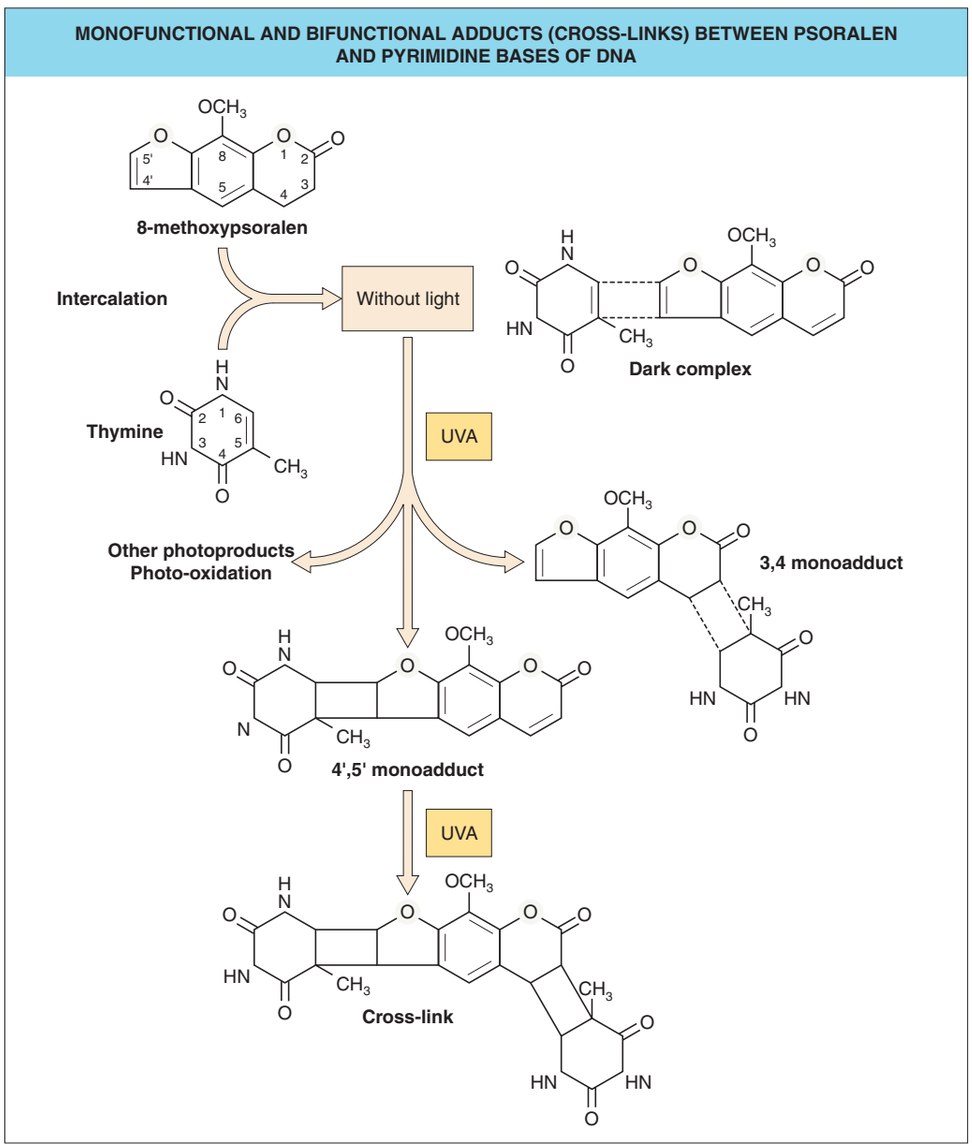


**Fig. 134.10** Monofunctional and bifunctional adducts (cross-links) between psoralen and pyrimidine bases of DNA.



Downloaded for Anonymous User (n/a) at Egyptian Knowledge Bank from ClinicalKey.com by Elsevier on March 10, 2024. For personal use only. No other uses without permission. Copyright ©2024. Elsevier Inc. All rights reserved.

explain its efficacy in CTCL as well as in inflammatory skin diseases. Although much is known about pathways and mechanisms in psoralen photosensitization, the interactions and relative contributions to the clearing of a specific disease are not well understood.

Psoralens also stimulate melanogenesis. This involves the photoconjugation of psoralens to DNA in melanocytes, followed by mitosis and subsequent proliferation of melanocytes, increased formation and melanization of melanosomes, enhanced transfer of melanosomes to keratinocytes, and increased synthesis of tyrosinase via stimulation of cAMP activity (see Ch. 65).

## Action Spectrum and Light Sources

The action spectrum for 8-MOP-induced delayed erythema has its maximum activity in the 330–335 nm range and the antipsoriatic activity of 8-MOP (plus UVA) appears to parallel this erythema action spectrum[44]. Conventional therapeutic UVA fluorescent tubes and broad-spectrum metal halide lamps, which are filtered in the UVB and UVC range, effectively cover the psoralen action spectrum. The typical fluorescent UVA lamp used for PUVA therapy peaks at 352 nm and emits ~0.5% in the UVB range (Fig. 134.11). Major advantages of mercury halide units are the stability of output and their high irradiance, enabling shorter treatment times.

UVA doses are given in J/cm$^2$, instead of mJ/cm$^2$ used for UVB, and are usually measured with a photometer with a maximum sensitivity at 350–360 nm. Within the phototherapy cabinet, the irradiance must be relatively uniform to ensure that the dose does not vary at different anatomic sites. UVB emission should be kept low enough to avoid erythemogenic UVB doses so that sufficient UVA is absorbed to activate the psoralen photosensitivity reaction.

## Photobiologic Effects of PUVA

PUVA treatment produces an inflammatory response that manifests as delayed phototoxic erythema. The reaction depends on the dose of drug, the dose of UVA, and the individual's sensitivity (skin type). More recently, it was shown that changes in 8-MOP dose had no detectable effect on the maximum slope of the PUVA erythema dose–response curve. Thus, 8-MOP dose changes within individuals, over a narrow but clinically relevant range, appear to significantly alter the threshold response to PUVA erythema but not the rate of increase in erythema with increasing UVA dose[45].

The time course for PUVA erythema differs markedly from sunburn or UVB erythema; the latter appears after 4–6 hours and peaks 12–24 hours after exposure to UVB. PUVA erythema does not occur before 24–36 hours and it peaks at 72–96 hours or even later after exposure. It has a shallower dose–response curve than UVB erythema (by a factor of ~2) and this difference is maintained even at the time of maximum erythema[46]. PUVA erythema persists for longer periods of time (lasting up to more than 1 week) and it consists of a deeper red, even a violaceous, hue. Severe reactions may lead to blistering and to superficial skin necrosis. Overdoses of PUVA are frequently followed by edema, intense pruritus, and sometimes by a peculiar stinging sensation in the affected skin area. At present, erythema is the only clinical parameter that allows for an assessment of the magnitude of the PUVA reaction and then determination of UVA dose adjustments[2].

Pigmentation, the second important effect of PUVA, may develop without clinically evident erythema, especially when oral TMP is used. In normal skin, PUVA pigmentation peaks about 7 days after exposure and may last from several weeks to months. As with sun-induced tanning, the individual's ability to tan is genetically determined, but the dose–response curve is much steeper. A few PUVA exposures result in a much deeper tan than that produced by multiple exposures to solar radiation. When administering PUVA therapy for inflammatory and neoplastic disorders, an important strategy is to produce a clinical response prior to the induction of significant pigmentation.

## Treatment Protocols

### *Oral PUVA*

For oral PUVA, the general approach is to keep the dose of psoralen, as well as the interval between drug intake and UVA exposure, constant, and to vary the UVA dose according to the patient's sensitivity. A dosage of 8-MOP of 0.6 to 0.8 mg/kg body weight is administered orally 1–3 hours before exposure, depending on the absorption characteristics of the particular drug formulation (see above).

The initial UVA doses are selected either by skin phototyping[8,47] or by determining the minimal phototoxicity dose (MPD)[48]. In the US, skin reactivity to solar radiation is evaluated and patients are classified based on a skin phototype scheme according to their sunburn and tanning history. Therapeutic doses of UVA are then given according to an empirical scheme based on this classification[8,45] (Table 134.4). In Europe, until recently, the most widely used approach consisted of MPD determination analogous to MED determination. The MPD is defined as the minimal dose of UVA (following psoralen ingestion) that produces a barely perceptible, but well-defined, erythema. The doses range from 0.5 to 5 J/cm$^2$ if oral 8-MOP is used. Erythema readings are performed 72 to 96 hours after irradiation, when the phototoxicity reaction usually peaks. As with the MED, the MPD is determined on previously non-sun-exposed skin (lower back or buttocks). Since determining the MPD is rather time-consuming and can take up to a week to perform, it has been abandoned for practical reasons in most European phototherapy centers and replaced by phototyping. In several phototherapy guidelines, MPD testing is still recommended but not considered to be mandatory.

Oral PUVA should not be used in patients with hepatitis because a slower metabolism of psoralens may prolong photosensitivity. Impaired renal function may also reduce psoralen excretion.

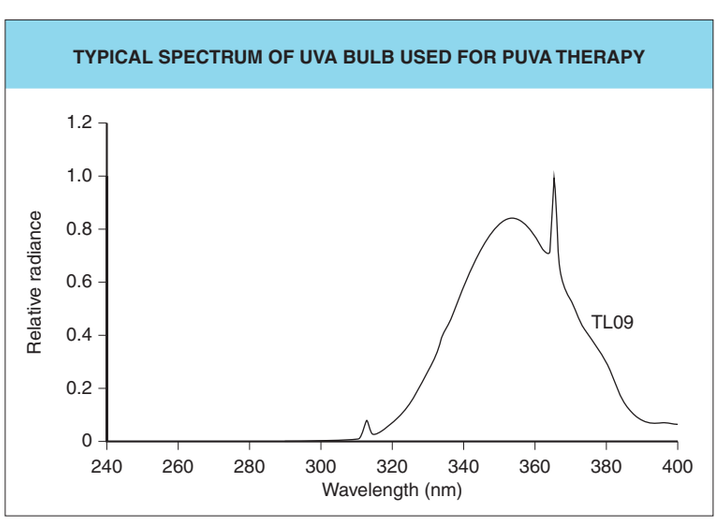


**Fig. 134.11 Typical spectrum of a UVA bulb (Philips TL09) used for PUVA therapy.**

SKIN PHOTOTYPES AND INITIAL DOSE OF UVA FOR PUVA THERAPY

| Skin phototype* | Skin reaction | Recommended initial dose (J/cm$^2$) |
|---|---|---|
| I† | Always burns, never tans | 0.25–0.5 |
| II | Always burns, but sometimes tans | 0.5–1.0 |
| III | Sometimes burns, but always tans | 1.5 |
| IV | Never burns, always tans | 2.0 |
| V‡ | Moderately pigmented skin | 2.5 |
| VI | Darkly pigmented skin | 3.0 |

*Types I–IV are determined by history; types V and VI by physical examination (skin color).
†Patients with erythrodermic psoriasis are to be classified as skin phototype I for determination of UVA dosage.
‡Patients with this phototype should be classified into a lower skin phototype category if the sunburning history so indicates.

**Table 134.4 Skin phototypes and initial dose of UVA for PUVA therapy.** These irradiation doses are based upon an oral 8-MOP dose of 0.6–0.8 mg/kg.



Downloaded for Anonymous User (n/a) at Egyptian Knowledge Bank from ClinicalKey.com by Elsevier on March 10, 2024. For personal use only. No other uses without permission. Copyright ©2024. Elsevier Inc. All rights reserved.

### *Bath PUVA*

Bath-water delivery of psoralens has become increasingly popular because it provides uniform drug distribution over the skin surface, very low psoralen plasma levels, and a rapid elimination of free psoralens from the skin, thereby reducing the period of photosensitivity. Due to the absence of systemic photosensitization, bath-water delivery of 8-MOP circumvents gastrointestinal side effects and potential ocular effects. Skin psoralen levels are highly reproducible and photosensitivity lasts no more than 2 hours. However, peak erythema is delayed as compared to the oral route; therefore erythema readings should be performed 96 to 120 hours after irradiation, which is the major reason why MPD determination has been replaced by phototyping in most phototherapy centers. The higher incidence of unwanted phototoxicity can be prevented by a lower starting dose and more cautious dosimetry during the initial treatment phase.

Originally, bath PUVA was performed with TMP, but 8-MOP is now being used as well. Bath PUVA consists of 15–20 minutes of whole body (or hand and foot) immersion in solutions of 0.5–5.0 mg of 8-MOP per liter of bath water. Irradiation has to be performed immediately thereafter, as photosensitivity decreases rather rapidly. However, one must take into account that, unlike with oral PUVA, the phototoxic threshold *declines* early on during treatment (this may be due to persistent psoralen adducts)[2]. Thus, at the onset, dose increments should be done more cautiously.

### *Topical PUVA*

Application of 8-MOP (0.1%–0.01%) in creams, ointments, or lotions, followed by UVA irradiation, is effective but has several disadvantages. The non-uniform distribution on the skin surface may produce unpredictable phototoxic erythema reactions, and inadvertent application to surrounding uninvolved skin can lead to cosmetically unacceptable hyperpigmentation. Furthermore, if numerous lesions are present, the application is laborious and time-consuming, and the treatment does not prevent the development of new active lesions in previously unaffected, untreated areas. Finally, extensive application ("paint" PUVA) of a 0.15% 8-MOP emulsion was found to cause plasma levels comparable to those detected with oral ingestion. Therefore, topical PUVA utilizing psoralen creams, ointments, or lotions is now reserved primarily for dermatoses of the palms and soles.

## Initial Treatment (Clearing) Phase

The initial treatment phase is defined as the treatment period until clearing of the disease is achieved; repeated exposures are required, with gradual dose increments as pigmentation develops. Doses that are too low frequently result in failure of treatment, except in those diseases in which induction of pigmentation is the desired objective. In most dermatoses amenable to PUVA, the frequency of treatments should be reduced after satisfactory control of the disease.

If MPD testing is performed, a safe initial therapeutic dose for oral PUVA is 50%–70% of the MPD. For bath PUVA, it is advisable to start at only 30% of the MPD, because photosensitivity is up to 10 times higher than with oral PUVA (Fig. 134.12). As noted previously, nowadays, most centers start with doses based on the patient's skin phototype.

Irradiations are given two to four times weekly. Dose increments are performed no more often than twice a week (at least 72 hours apart) and never during the first week of treatment (if initial dose is based on MPD), in order to avoid an accumulation of delayed cutaneous phototoxicity. Although not necessary for therapeutic success, a minimally perceptible erythema is considered a clinical indicator of adequate dosimetry. There exists no rigid scheme for dose increments; the major parameter for dose adjustments should be the clinical response of the disease. It is essential to note that with bath PUVA, the MPD can even decrease during the first days after initiation of treatment by up to 50%, but then increase at later stages. This may be due to persistent psoralen adducts which are converted into cross-links upon subsequent exposures.

In the absence of erythema, the UVA dose can be increased safely by 30% in both oral PUVA and bath PUVA (see Fig. 134.12). However, because of erythema formation and/or an adequate treatment response, some patients will not require dose adjustments over prolonged periods of time.

## Maintenance Phase

The purpose of maintenance therapy is to prolong the duration of clinical remission. In the original European regimen, maintenance therapy consisted of one month of twice-weekly treatments utilizing the final UVA dose administered during the clearing phase, followed by another month of once-weekly exposures. However, results of a more recent study indicated that short-term maintenance therapy was not

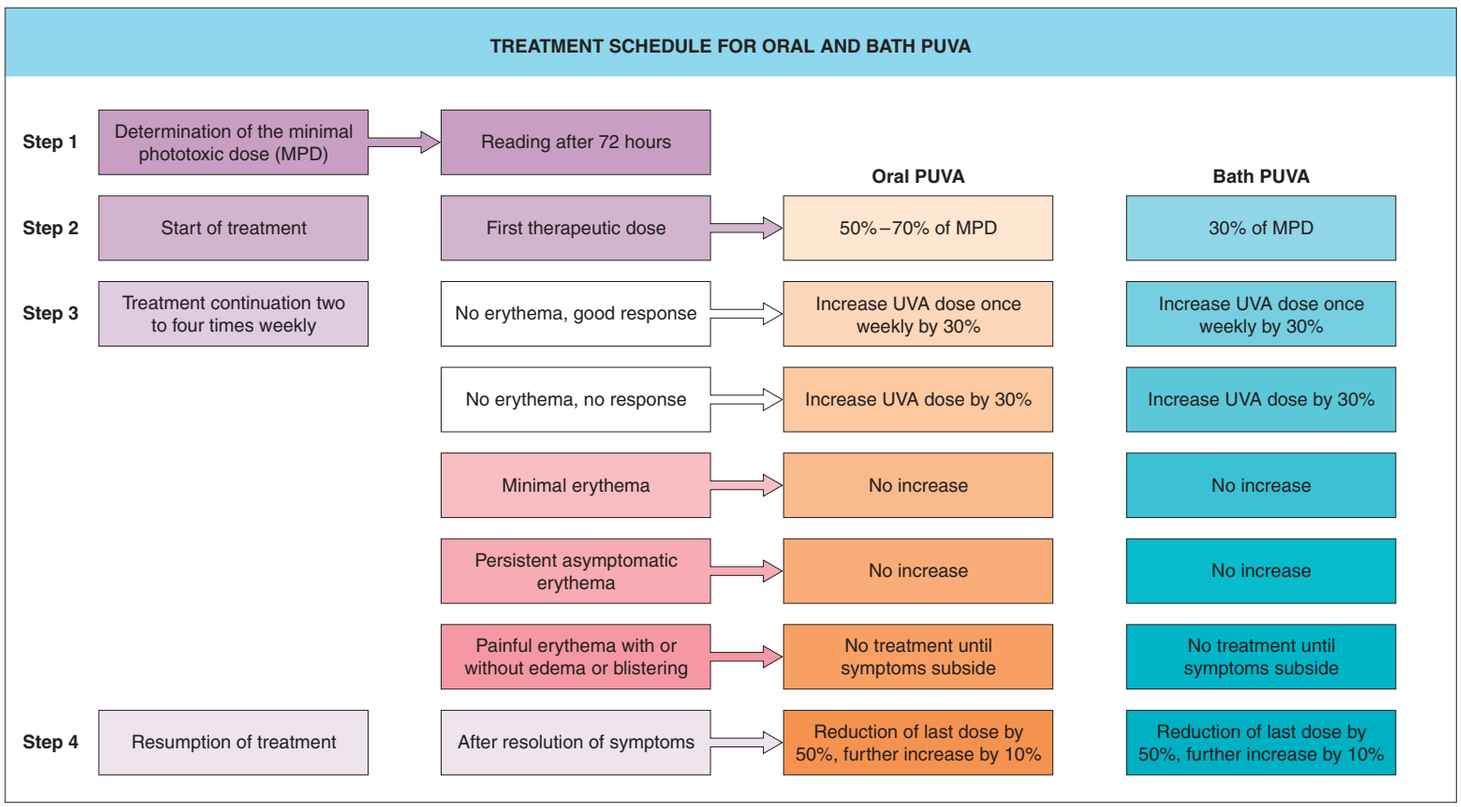


**Fig. 134.12 Treatment schedule for oral and bath PUVA.**



Downloaded for Anonymous User (n/a) at Egyptian Knowledge Bank from ClinicalKey.com by Elsevier on March 10, 2024. For personal use only. No other uses without permission. Copyright ©2024. Elsevier Inc. All rights reserved.

effective in preventing early relapses of psoriasis[49]. For MF, many institutions recommend some form of permanent maintenance therapy, but there is a lack of prospective studies to validate this recommendation. Perhaps a once-monthly treatment would be a feasible compromise.

Mild relapses during the maintenance phase are handled by temporarily increasing the frequency of treatments; in the case of a severe relapse, the original clearing phase schedule must be resumed until clearing is once again achieved. A disadvantage of maintenance therapy for patients in remission is the potential to overtreat the patient and to increase the potential for long-term toxicity that is related to the total cumulative dose of PUVA.

## PUVA for Psoriasis

Basically, all types of psoriasis respond to PUVA (Fig. 134.13), although the management of erythrodermic or generalized pustular psoriasis is more difficult[2]. Both the US and the European regimens have proven to be highly efficient and therefore have remained in use, although with the advent of systemic immunomodulators ("biologics"; see Ch. 128), phototherapy for all types of psoriasis has lessened.

Three studies have compared bath-water delivery of 8-MOP with oral administration[50–52]. In two reports, initial doses were determined by skin phototyping and treatments were given two to three times weekly. Dosage increments were made with every treatment in the first study[50], whereas smaller increments were performed every third treatment in the second[51]. Patients in the third study were treated according to the guidelines of the standard European regimen for oral PUVA; this group had the lowest incidence of treatment failures and overdose episodes[52]. Relative to the results obtained with oral PUVA, bath PUVA showed equal clearing rates with lower numbers of exposures. The greater therapeutic efficacy could be due to a higher penetration of psoralens through the abnormal stratum corneum overlying psoriatic plaques as compared with healthy perilesional skin where phototoxicity is monitored during the therapy. The incidence of erythema and pruritus was similar or lower with bath PUVA as compared to oral therapy. In all the investigations, episodes of systemic intolerance such as nausea and vomiting were recorded only with oral PUVA[2].

PUVA alone can produce a definite remission in many cases of psoriasis, but a considerable number of patients require combination therapy (see below).

**Fig. 134.13 PUVA treatment for psoriasis (four times weekly). A** Before treatment. **B** After 6 weeks of treatment.

## Combination Treatments

### *Topical combination*

As with UVB phototherapy, PUVA can be combined with other treatment modalities to improve efficacy and to reduce potential side effects[2]. Topical adjuvant therapies include corticosteroids, anthralin, tar, and vitamin D analogues (see Chs. 125 & 129). However, some patients are reluctant to "retry" topical agents that previously proved unsuccessful when used alone.

### *Methotrexate, cyclosporine, systemic immunomodulators ("biologics")*

The combination of PUVA and methotrexate (MTX) during the clearing phase reduces the duration of treatment, number of exposures, and cumulative UVA dose, and it is also effective in clearing patients unresponsive to PUVA or UVB alone[53]. To date, no increased risk of keratinocyte carcinomas has been reported for this combination. In contrast, cyclosporine plus PUVA has been clearly shown to dramatically enhance cutaneous carcinogenesis. Thus, this latter combination should be categorically discouraged[53], including the use of cyclosporine subsequent to PUVA therapy. Presently, there are no studies evaluating the safety and efficacy of biologics plus PUVA.

### *Retinoids*

The combination of PUVA with systemic retinoids (RePUVA) is one of the most potent therapeutic regimens for psoriasis. The therapeutic efficacy of PUVA therapy is significantly enhanced upon combination with oral retinoids (acitretin [0.5–0.75 mg/kg] or isotretinoin [0.75–1 mg/kg]) that are administered daily for 5–10 days before PUVA is started, with the combination continued throughout the clearing phase. RePUVA reportedly can reduce the number of exposures by one-third and the total cumulative UVA dose by more than one-half. RePUVA can also clear "poor PUVA responders"[2].

The underlying mechanism of the synergistic action of retinoids plus PUVA may be a reduction in the inflammatory infiltrate and an accelerated desquamation of the psoriatic plaques, thereby optimizing the optical properties of the skin. In theory, retinoids may also reduce the long-term carcinogenic risk of PUVA by reducing the number of exposures and providing chemoprevention against skin cancers. Some evidence for this was presented in a study where patients with psoriasis treated with PUVA in combination with systemic retinoids showed a reduced risk of SCC but not a significantly altered incidence of BCC[54].

Short-term side effects of retinoids are completely reversible upon discontinuation, and long-term toxicity is not relevant because of the limited duration of their use (until clear). The potential teratogenicity of retinoids represents a serious concern. For women of childbearing age, the use of isotretinoin is an option, because contraception is only necessary for 1–2 months after discontinuation of therapy, as opposed to acitretin, which requires two subsequent years of contraception[2].

## PUVA for Cutaneous T Cell Lymphoma, in Particular Mycosis Fungoides

Based on the empirical beneficial effect of natural sunlight on early stage MF, Gilchrest et al.[55] first reported the successful use of PUVA for MF. Patients with unsatisfactory responses to other therapies and histologically confirmed plaque or tumor stage MF or the erythrodermic form of CTCL were subjected to PUVA. Complete clearing was observed, except



Downloaded for Anonymous User (n/a) at Egyptian Knowledge Bank from ClinicalKey.com by Elsevier on March 10, 2024. For personal use only. No other uses without permission. Copyright ©2024. Elsevier Inc. All rights reserved.

in those areas that were shielded from UVA exposures, thus excluding the possibility of spontaneous remission. This also indicated that the therapeutic effect of PUVA was local rather than systemic.

Numerous studies followed which addressed the rates of initial response and average duration of remission in relation to the stage of MF, the efficacy of PUVA compared with other established treatment options, the efficacy of combination treatments, the mechanisms responsible for the therapeutic effects, and the risk of short- and long-term side effects[2].

Treatment schedules and dosimetry in the photochemotherapy of MF are essentially the same as for psoriasis, consisting of three phases – clearing, maintenance, and follow-up. Some authors suggest that remission should be confirmed by histologic examination of previously involved areas. In some institutions, maintenance therapy includes two exposures per week for one month and one exposure per week for another month. If still in remission, therapy is discontinued and the patient is monitored monthly and then bimonthly. If a relapse occurs, the patient is again treated with three or four PUVA exposures per week until complete clearing. However, other investigators advocate permanent maintenance treatment consisting of treatments once monthly or every other month, as it appears that PUVA treatment is not curative. Since the course of MF varies considerably from patient to patient, the final answer remains to be determined.

Clinical experience indicates that patients benefit most from individualized schedules. For example, a recent study described the administration of a low frequency regimen (2×/week) for early MF (stage IA–IIA)[56]. Oral PUVA was administered for up to 24 weeks in 27 patients; 19 complete and 8 partial remissions were observed and the average cumulative UVA dose was rather low (78.5 J/cm$^2$). Eleven of the 19 patients with a complete remission underwent maintenance therapy (14 exposures over 9 months), with 7 of those still in remission after one year. In comparison, 7 of 8 patients who did not receive maintenance therapy experienced a relapse.

Several studies involving large patient cohorts have provided information on the initial response rates of PUVA treatment in relation to disease stage. Overall, the best initial complete response rates were obtained for stages IA (~90%), IB (~76%) and IIA (~78%), as compared to stages IIB and III (~60%). There was some heterogeneity in results and the use of different treatment protocols, psoralen preparations, and light sources may have contributed to this finding. Only a few patients with stage IV disease have been treated with PUVA monotherapy, because, in this stage, PUVA is generally considered to be only a palliative or adjunctive therapy. Relapses usually respond to PUVA in the same manner as the initial response. Clinical remissions appear to be directly related to phototoxic destruction of the malignant infiltrate. Thus, complete clearing may be induced when the cells are confined to the epidermis and the superficial dermis and do not exceed the depth of UVA penetration into the skin. Patients with tumor stage MF exhibit a high rate of early recurrences, which require permanent maintenance treatment; often only the combination of PUVA with local radiotherapy and/or systemic chemo-immunotherapy can result in complete tumor resolution.

In summary, the data thus far indicate that PUVA is an excellent treatment option for early stage (IA–IIA) CTCL (Fig. 134.14). High rates of complete clearing can be achieved and a substantial percentage of patients remain free of disease for many years. In a meta-analysis of seven studies that compared PUVA versus NB-UVB for the treatment of early MF (IA–IIA), 778 patients (527 PUVA, 251 NB-UVB) were analyzed[57]. Complete remission was achieved in 74% of the patients in the PUVA group and 62% in the NB-UVB group; the remission-free interval ranged from 10 to 45 months (mean 33 months) in the PUVA group compared to 5 to 24 months (mean 15 months) in the NB-UVB group. The significantly longer remissions rates may be one of the reasons why in some treatment guidelines PUVA is regarded as the therapy of choice in early stage MF[58].

In advanced stages (IIB–IVB) of MF, PUVA is not sufficient as monotherapy, but as an adjunctive treatment it can reduce the tumor burden in the skin and can improve the quality of life for patients. Presently, no therapeutic regimen is known to arrest eventual progression of advanced stages of MF to tumor formation, dissemination, and a fatal outcome. Prolonged remissions have been observed with combinations of PUVA plus systemic retinoids (e.g. bexarotene[59]) or IFN-α-2a[60,61]. Possible long-term side effects related to frequent PUVA treatments are probably less meaningful for patients with CTCL compared with patients who have benign disorders.

**Fig. 134.14 PUVA treatment for cutaneous T cell lymphoma (mycosis fungoides). A** Before treatment. **B** After 12 weeks of treatment that was four times weekly.

While PUVA therapy is very effective in inducing remission as long as the lymphoma is confined to the skin, the impact of this therapy on the natural course of CTCL and on patient survival is not yet determined.

## PUVA for Vitiligo

As mentioned previously, vitiligo was the first disease treated with an ancient form of psoralen photochemotherapy in India and Egypt. PUVA in its modern form stimulates melanogenesis as well as melanocyte



Downloaded for Anonymous User (n/a) at Egyptian Knowledge Bank from ClinicalKey.com by Elsevier on March 10, 2024. For personal use only. No other uses without permission. Copyright ©2024. Elsevier Inc. All rights reserved.

proliferation and migration, and it reconstitutes the normal skin color in more than 50% of vitiligo patients.

### *Treatment protocols and results*

Nowadays, oral 8-MOP is the photosensitizer most frequently used, followed by exposure to sunlight or artificial UVA radiation. In the past, if sunlight were the radiation source, oral TMP was the preferred photosensitizer due to its weaker phototoxicity. To induce repigmentation, patients need constant long-term therapy. It is crucial that the patient understands that PUVA, like other vitiligo therapies, may require months or even years to achieve a satisfactory result. Overly optimistic prognoses regarding therapeutic efficacy and length of time to produce adequate repigmentation should be avoided. The patients must also be aware that the treatments stimulate the pigmentation of normal skin, which will intensify the contrast between normal and vitiliginous skin.

Treatments should be given at least twice a week, but not more than three times, with at least one day between treatments. If there is no response after 4–5 months or ~30–40 treatments, PUVA should be terminated. Responsiveness is defined as development of multiple perifollicular macules of repigmentation, or, in the case of small (<2 cm) lesions, contraction in size. If treatment is discontinued, reversal of acquired repigmentation may occur unless the lesion has completely repigmented. Completely repigmented areas can be stable for a decade or more without relapse.

Photochemotherapy with topical 8-MOP can be used in patients with small lesions (<5% total body surface area) or in children in whom one may hesitate to use systemic PUVA. The therapy must be done in an office setting, since home treatment involves a high risk of severe phototoxic side effects. Topical 8-MOP preparations (0.0005%–0.005% 8-MOP in a cream or ointment base) are applied evenly on the treatment area 30 minutes prior to irradiation. Exposure times (beginning at $\leq 0.25\,J/cm^2$) are increased weekly in increments of $0.25\,J/cm^2$ unless marked erythema occurs. Once- to twice-weekly treatments are recommended. With topical PUVA, the vehicle plays a major role in delivery and resulting cutaneous psoralen levels. Solutions should be avoided as they can "run", producing hyperpigmented streaks. Application of sunscreen to the surrounding uninvolved skin prior to application of the topical psoralen can reduce hyperpigmented rims.

Patient selection appears to be critically important. For oral PUVA, the patients should be ages 10–12 years or older, and for all forms, they must be available for 12–24 months of continuous therapy. Lips, distal dorsal hands, fingers and toes, palms, soles, and nipples are very refractory to treatment, as are large areas with only white hairs. Patients need to be made aware of this fact.

Stable disease, i.e. nonprogressive for at least 6 months to a year, is usually easier to treat. On average, a complete treatment regimen consists of at least 150 exposures. However, because of the different response rates in different body areas, total repigmentation is only rarely achieved, and ~30% of patients do not respond at all, despite months of therapy. As mentioned above, in a trial involving patients with non-segmental vitiligo, NB-UVB therapy resulted in a better color match when compared to oral PUVA[15]. As a result, the use of NB-UVB has increased while PUVA therapy for vitiligo has waned in most phototherapy centers.

## PUVA for Atopic Dermatitis (See Ch. 12)

Many patients with moderate, severe, and even erythrodermic forms of atopic eczema can benefit from PUVA therapy[53]. The treatment guidelines are essentially the same as for psoriasis, but patients may develop a temporary flare of their dermatitis during the initial treatment phase. Also, atopic dermatitis is more difficult to treat than psoriasis and quite often a higher number of treatments is required. Although atopic dermatitis may be cleared by PUVA, recurrence rates are high and rapid, requiring frequent maintenance exposures. However, in young patients, long-term maintenance therapy should be avoided. A combination of PUVA with topical corticosteroids appears to be superior to PUVA alone in maintaining remissions, and in a more recent study involving patients with severe atopic dermatitis, PUVA provided better short- and long-term responses than did medium-dose UVA1. These latter results require further confirmation. Due to the introduction of systemic immunomodulators such as dupilumab to treat moderate-to-severe atopic dermatitis, the importance of PUVA as a therapeutic approach will likely decrease in the future.

## PUVA for Lichen Planus (See Ch. 11)

In generalized lichen planus, PUVA can provide an effective alternative to systemic corticosteroids. Studies have pointed to an overall response rate between 50% and 90%, suggesting that lichen planus is less responsive than psoriasis to PUVA. In addition, more treatment sessions and higher cumulative UVA doses were generally necessary for complete remission and not all patients responded satisfactorily. Marked postinflammatory hyperpigmentation may impair the final cosmetic result. An exacerbation during PUVA treatment has been reported in a few patients. Bath PUVA also works in lichen planus, and a combined RePUVA regimen (as is used for psoriasis) may accelerate clearing in disseminated and particularly keratotic forms of lichen planus. Compared to NB-UVB, oral PUVA led to a better initial clinical response rate, but both were effective treatments and produced similar long-term outcomes[62].

## PUVA for Graft-Versus-Host Disease (see Ch. 52)

Due to clinical and histologic similarities between idiopathic lichen planus and lichenoid GVHD, PUVA treatment was evaluated for the latter[63]. Beneficial effects were observed in patients who had not responded to conventional immunosuppressive therapy alone. PUVA can also improve acute GVHD[64]. Results of PUVA therapy for scleroderma-like variants of cutaneous GVHD are controversial[65]. In our experience, the more localized and circumscribed morpheaform lesions appear to respond to PUVA fairly rapidly, with softening of the associated sclerosis. However, the more advanced and widespread sclerodermoid form hardly responds to PUVA.

In contrast to other conditions, PUVA may exert not only local but also systemic effects, since improvement of mucosal erosions was observed during treatment of chronic lichenoid GVHD with PUVA, but this could have also been coincidental. Apparently, there is no improvement of GVHD of other organs, e.g. liver and gut. Of note, deterioration of liver GVHD has not been reported thus far. This is important, since psoralens are metabolized by the liver.

The therapeutic regimen used for the treatment of chronic GVHD is basically the same as for psoriasis. UVA doses should not be increased too aggressively, in order to avoid erythema and possible (re)activation of GVHD. The UVA dosage is increased by no more than $0.5\,J/cm^2$ every second to fourth exposure and patients are treated three to four times weekly. After clearing of skin lesions, exposures are reduced according to the maintenance schedule outlined for psoriasis.

There may be a slight overall increased risk of cutaneous malignancies in hematopoietic stem cell recipients, but much less than in solid organ transplant patients who receive long-term immunosuppression. If patients are receiving long-term prophylactic treatment with voriconazole, switching to posaconazole should be considered in order to reduce possible enhancement of SCC formation.

## PUVA for Urticaria Pigmentosa (See Ch. 118)

PUVA causes a temporary involution of cutaneous mastocytosis[66,67]. The treatment results in loss of Darier's sign, relief of itching, and flattening and sometimes disappearance of cutaneous macules and papules. Surprisingly, even systemic symptoms such as histamine-induced migraines and flushing fade gradually as treatment is continued[66]. In most patients, the clinical manifestations recur several months after discontinuation of PUVA. The recurrences respond as well as the original lesions, and clearing of signs and symptoms can again be achieved. In children, PUVA is also often helpful, and appears to be justified in widespread, disabling mastocytosis. To avoid sudden mediator release from mast cells, a PUVA regimen of gradually increasing doses, especially during the initial phase, seems advisable, although the therapy should otherwise be undertaken according to the usual guidelines.

## PUVA for Miscellaneous Dermatoses

Both acute and chronic pityriasis lichenoides[22] respond to photochemotherapy and favorable results have been reported for lymphomatoid papulosis[22,68]. Nevertheless, the experience with these conditions is limited to anecdotal cases. In pityriasis rubra pilaris, the results are



Downloaded for Anonymous User (n/a) at Egyptian Knowledge Bank from ClinicalKey.com by Elsevier on March 10, 2024. For personal use only. No other uses without permission. Copyright ©2024. Elsevier Inc. All rights reserved.

quite inconsistent. Some patients seem to respond well[22], while others may flare and some require combination treatment with retinoids or methotrexate. Generalized granuloma annulare has been reported to clear completely, but long-term maintenance treatment was required to maintain remissions[69]. There were initial reports of both topical and systemic PUVA leading to regrowth of hair in patients with alopecia areata in whom exposures were localized to the alopecia areas. The number of treatments required for regrowth varied widely, and circumscribed lesions responded better than did total alopecia. However, follow-up studies of larger patient groups concluded that PUVA is generally not effective in alopecia areata[70,71], which is in accordance with our own experience. Localized scleroderma and pansclerotic morphea have been successfully treated with bath PUVA and oral PUVA[72].

## PUVA for Photodermatoses

Tolerance to sunlight can be induced in several photodermatoses with NB-UVB (see above) or PUVA[73]. Although NB-UVB is tried first due to safety concerns, PUVA represents a very effective preventive treatment for polymorphous light eruption (PMLE; via hardening)[74]. In ~70% of patients with this condition, a 3- to 4-week course of PUVA suffices to suppress the disease upon subsequent exposure to sunlight. PUVA induces pigmentation rapidly and intensively at relatively low (suberythemogenic) UVA doses that usually remain well below the threshold doses for eliciting the PMLE. About 10% of the patients develop typical lesions during the initial phase of PUVA, and as with UVB phototherapy, interventions include interruption of treatment, reduction in the UVA dose, and application of topical corticosteroids.

The therapeutic value of preventive photochemotherapy for PMLE has to be balanced against its potential long-term side effects. Given the fact that very few treatments and low cumulative UVA doses (ranging from 15 to 40 J/cm$^2$ per treatment course, depending on skin type and photosensitizer) are required for photoprotection and that PMLE can severely restrict outdoor activities, PUVA treatment of PMLE is justified when other preventive measures (e.g. sunscreens, NB-UVB) fail[74].

There is also some experience with PUVA prophylaxis of other photodermatoses. In solar urticaria, PUVA therapy is an effective preventive treatment and is certainly better than antihistamines[75]. Sensitivity to sunlight can be decreased by 10-fold or more after a single treatment course. The suppressive effect may last throughout the summer, depending on regularly repeated sunlight exposures. Problems may occur during the first several PUVA exposures, since in some patients the urticaria threshold dose appears to be lower than their MPD. In these cases, stepwise UVA irradiation of single quadrants of the body a few hours before each PUVA treatment has proven useful[75]. PUVA is then administered during the refractory period. Of note, UVA rush hardening appears to be equally effective as PUVA, with the advantage of inducing the hardening effect and providing protection within a few days[21].

Successful photochemotherapy has also been reported in occasional patients with chronic actinic dermatitis and hydroa vacciniforme[76].

## Side Effects and Long-Term Hazards of PUVA

As discussed above, oral 8-MOP has a high incidence of nausea (30% of patients) and vomiting (10% of patients), and this may occasionally require discontinuation of the medication. These side effects are more common with liquid than with crystalline preparations, probably because of higher psoralen serum levels.

The short-term side effects of the combined action of psoralens plus UVA radiation consist of redness, swelling, and occasionally blister formation as can be seen with excessive sunburns. Generalized pruritus or tingling sensations may herald phototoxic side effects. When large areas of skin are affected, systemic symptoms of excess phototoxicity such as fever and general malaise may occur. Nonsteroidal anti-inflammatory drugs and topical and systemic corticosteroids may be required to alleviate these symptoms, but they have to be given early. Because of high epidermal psoralen concentrations, such overdosage phenomena are more common after topical psoralen application. Accumulation of phototoxic effects after several consecutive UVA exposures is also more common with topical PUVA.

Some patients experience persistent pruritus during PUVA treatment, particularly after slight UVA overdosage, and in rare cases, a stinging pain may develop in circumscribed areas. PUVA-induced skin pain unrelated to actual phototoxic burns occurs rarely, but it may necessitate discontinuation of treatment. The mechanism is unknown and the symptoms are unresponsive to antihistamines. Usually, these complaints subside slowly upon continuation of treatment.

### *Ophthalmologic effects*

Eye protection is mandatory during UVA exposure, and UVA-opaque glasses are required for ambient exposure until the evening of the treatment day. UVA penetrates into the ocular lens and potentially could induce cataracts by forming psoralen-protein photoproducts. The higher permeability of the ocular lens at a younger age led to the relative contraindication of oral PUVA in children younger than 12 years of age. Despite the experimental data indicating a risk of premature cataract formation, clinical evaluation has shown no increase in lens opacities even in patients who neglected to practice careful eye protection[77]. Obviously, there is no risk with topical or bath PUVA.

### *Laboratory data*

Because psoralens can cause liver damage in laboratory animals when given in excessive doses, concern was expressed in the past regarding possible hepatotoxic effects in humans. Several large-scale studies demonstrated no significant abnormal laboratory findings in patients receiving PUVA over prolonged periods of time[47,48]. In particular, serial laboratory examinations performed over a period of several years have not revealed any substantial evidence for an impairment of hepatic function. Liver biopsies after 1 year of therapy did not show signs of hepatotoxicity. Anecdotal case reports of hepatitis during PUVA treatment were most likely unrelated to therapy. Several large-scale studies have negated a possible relationship between PUVA therapy and the occurrence of anti-nuclear antibodies[78].

### *Potential long-term risks of PUVA*

Repeated phototoxic injury to the skin can be expected to result in cumulative actinic damage regardless of whether it is induced by sunlight, artificial UV radiation, or PUVA. Although the precise action spectrum of actinic damage has not been determined, epidermal changes are attributed to UVB and dermal changes more to UVA, because the latter penetrates more deeply into the skin. Thus, chronic exposure to PUVA may produce changes in the skin that generally resemble those known as dermatoheliosis and may add to the injury induced by sunlight. High cumulative doses of whole body UVB or PUVA result in pigmentary changes, xerosis, loss of elasticity, wrinkle formation, and actinic keratoses. Additionally, PUVA may induce profuse formation of dark stellate lentigines (Fig. 134.15), termed PUVA lentiginosis[48]. These lentigines result from repeated and prolonged treatment and are commonly associated with high cumulative doses of UVA and a high number of treatments. So far, no increased risk of cutaneous melanoma

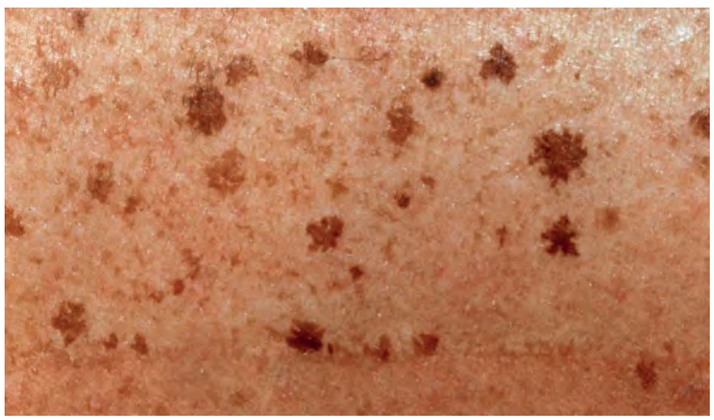

**Fig. 134.15 PUVA lentigines.** These develop after repeated PUVA treatments over several years and usually within a background of photodamaged skin.



Downloaded for Anonymous User (n/a) at Egyptian Knowledge Bank from ClinicalKey.com by Elsevier on March 10, 2024. For personal use only. No other uses without permission. Copyright ©2024. Elsevier Inc. All rights reserved.

associated with these lentigines has been recorded, but the cosmetic effect may be quite disturbing.

The major concern with prolonged and repeated phototherapeutic regimens is photocarcinogenesis. Therefore, from the onset, PUVA-treated patients were carefully monitored for the development of precursors and malignant skin tumors. Almost all data were obtained from psoriatics, since they represent the largest group of patients receiving PUVA.

The risk is certainly related to DNA damage, but PUVA-induced immunosuppression may play a role as well. In PUVA patients, the risk of SCC, but not of BCC, is significantly increased in comparison with matched controls, and the magnitude of the increase appears to be dose-dependent[79]. However, there is uncertainty regarding PUVA being the sole factor; many of the affected patients had previous exposure to excessive sunlight and to treatments with carcinogenic potential, including arsenic, UVB, and antimetabolite therapy[80]. Specifically, high levels of UVB exposure appear to increase the risk of keratinocyte carcinomas in PUVA-treated patients[81]. Of note, in non-White individuals who received long-term oral PUVA therapy, an increased risk of skin cancers was not observed[82]. In a more recent update from the original PUVA study, exposure to <150 PUVA treatments had, at most, modest effects on SCC risk and even high-dose exposure to PUVA did not greatly increase BCC risk[83].

According to a single study, the genitalia of male patients previously treated with tar and UVB appeared to be particularly susceptible to the carcinogenic effects of PUVA[84], but the risk seemed not to be increased if there had only been exposure to PUVA[85]. In a retrospective study from France comprised of 5400 patients treated between 1978 and 1998, no case of genital skin cancer was found, despite the fact that the genital area had not been protected during UVA exposure, raising the question as to whether genital shielding is absolutely necessary[86]. No increased risk of cutaneous carcinoma has so far been reported for patients treated with PUVA for vitiligo.

Only a few anecdotal cases of cutaneous melanoma have been described in long-term PUVA-treated psoriatics, and, to date, with one exception, no increased risk of melanoma has been observed in any reported large-scale study. However, Stern et al.[87] reported on the cohort of 1380 patients enrolled in the PUVA Follow-up Study (16-center study), and since 1975, 23 patients had developed 26 invasive or *in situ* cutaneous melanomas. Beginning 15 years after the initial exposure to PUVA, an increased risk of melanoma was observed in their cohort of PUVA-treated patients. However, the lead author concluded that perhaps PUVA has been judged unfairly. Its long-term risks have been subject to much greater scrutiny than the risks of other therapies utilized for severe psoriasis, such as methotrexate and particularly immunosuppressive therapies such as cyclosporine (CSA). Notably, several other US studies, as well as European studies, have not observed an increased risk of melanoma in patients treated with PUVA[88,89].

An increased risk of cutaneous SCC has been observed in solid organ transplant recipients who have received long-term CSA and in patients who have received CSA subsequent to PUVA therapy[90]. UVA-sparing, aggressive regimens without prolonged maintenance therapy may be safer than continuous non-aggressive regimens (see Table 134.4).

In a study of 944 Swedish and Finnish patients[91], bath PUVA with TMP appeared to have no relevant risk of carcinogenesis. In addition, no association between cutaneous carcinoma and 8-MOP bath PUVA was found in 158 Finnish psoriatic patients[92]. Perhaps related to lower cumulative UVA doses, these data on the long-term safety of bath PUVA are encouraging, but no premature conclusions should be drawn[93].

## UVB and PUVA in HIV-Infected Patients

Treatment of psoriasis with oral PUVA has not induced progression of HIV disease nor was there an increase in side effects. The conclusion is that PUVA may be safe for HIV-infected patients with psoriasis. Theoretical modeling of UVB- and PUVA-induced HIV promoter activation in human skin indicated that UVB was more likely than PUVA to activate viral transcription *in vivo*. Although further studies are needed to unequivocally establish the safety of both UVB and PUVA phototherapy in HIV-associated psoriasis, the benefits are considerable, particularly in those with severe psoriasis[94].

# EXTRACORPOREAL PHOTOCHEMOTHERAPY (PHOTOPHERESIS)

Extracorporeal photochemotherapy (photopheresis, ECP) was introduced in the early 1980s for the palliative treatment of erythrodermic CTCL[95]. Efficacy was observed in several uncontrolled clinical trials, and it was FDA-approved as a device in 1988 for the treatment of this disease. In 1994, at the International Consensus Conference on Staging and Treatment Recommendations for CTCL, ECP was recommended as the first line of treatment for patients with erythrodermic CTCL[96]. However, not all authorities agree (see Ch. 120).

Attempts to better characterize those CTCL patients who are more likely to respond to ECP revealed the following:

- There seems to be a significant linear association between response and CD4 : CD8 ratio. Patients with a ratio <10 are more likely to respond than are patients with a ratio >10.
- There is a marginally significant linear association between response and LDH level. Patients whose LDH is not elevated at the start of treatment tend to have a better response to ECP compared to patients with an elevated LDH[97].

ECP has also been advocated for the treatment of chronic cutaneous GVHD as well as acute GVHD[98,99].

## Treatment Protocols

The ECP procedure involves the passage of blood from an arm vein through a photopheresis machine and then back to the patient. Within the machine, a discontinuous flow cell separator harvests peripheral blood mononuclear cells (PBMC) within a buffy coat collection. The red cell fraction is returned to the patient without further treatment. 8-MOP solution is administered directly into the collection of the PBMC, thereby avoiding 8-MOP-induced nausea. The collection of PBMC is then exposed to 2 J/cm$^2$ of UVA and reinfused into the patient. This treatment is typically repeated on two successive days with 2- to 4-week intervals.

## Mechanism of Action

Despite the fact that ECP has been in use for over 40 years, the mode of action still remains enigmatic. It was postulated that the response of CTCL to ECP is due to the induction of an immune response against the malignant cells. More recent experimental results suggest that infusion of autologous haptenated cells, in which apoptosis was induced by 8-MOP/UVA, induces immunologic tolerance. The nature of this tolerance is due primarily to regulatory T cells, because transfer in an animal model conferred similar protection. The demonstration of the induction of regulatory T cells may explain why, in humans, ECP exerts a beneficial effect in a wide variety of diseases which would be amenable to such activity. The generation of antigen-specific regulatory T cells may explain why generalized immunosuppression has not been noted with ECP[100,101]. Monocyte-derived immature dendritic cells may play a role as well.

## Side Effects

Side effects of ECP are uncommon and consist of episodes of hypotension and vasovagal reflex due to volume shifts during treatments; the latter usually do not interfere with the treatment.

## Other Indications

A number of studies have been performed in order to evaluate the efficacy of ECP in inflammatory diseases other than CTCL and chronic GVHD where autoreactive T cells play a key role. Uncontrolled clinical trials have revealed variable success in selected entities such as atopic dermatitis, systemic sclerosis, pemphigus vulgaris, and systemic lupus erythematosus[102].



Downloaded for Anonymous User (n/a) at Egyptian Knowledge Bank from ClinicalKey.com by Elsevier on March 10, 2024. For personal use only. No other uses without permission. Copyright ©2024. Elsevier Inc. All rights reserved.